MAST CELLS AND HAIR GROWTH IN THE MOUSE

By T. Nay*

[*Manuscript received January* 24, 1956]

Summary

(i) In the skin of Naked, Crinkled, and occasionally, normal mice, the mast cell granules, or whole mast cells, located in subdermal connective tissue, become pigmented, the colour being the same as the colour of the hair of the animal in question.

(ii) In the skin of Crinkled mice, which have little hair growth, a great number of pigmented mast cells accumulate in the subdermal connective tissue.

(iii) The pigmented mast cell granules in Naked and Crinkled mice are engulfed by the growing hair follicle, and accumulated in the dermal papilla.

(iv) After the formation of pigment in the hair the dermal papilla appears depleted of pigmented granules.

(v) It is suggested that mast cells in the mouse are concerned in pigment formation.

I. Introduction

Since the discovery of mast cells by Ehrlich (1877) two important facts about their physiological function have been established. Holmgren and Wilander (1937), Jorpes, Holmgren, and Wilander (1937), and Hirt (1938), showed that the amount of heparin extracted from a tissue is proportional to the number of mast cells contained in it, indicating that the mast cells are the source of heparin. Riley (1953*a*, 1953*b*) and Riley and West (1953) found a correlation between the histamine content of normal and pathological tissues and the number of mast cells contained in them. Mast cell tumors proved to be extremely rich in histamine (Riley 1953*a*). But, as Riley (1953*a*) points out, "it seems possible, that the production of heparin and histamine are part of the mast cell function, and that there remains unproved a third function, which is probably a fundamental interaction between the mast cells and the connective tissue." The present paper is concerned with the relation of mast cells to the hair growth cycles.

II. Material and Methods

Over 100 mice were used in the course of the investigation. Of these, 25 were from the CR stock, which is maintained segregating for the *cr* (crinkled) gene (Grüneberg 1952), and the rest from the NM stock, which is maintained segregating for the *N* (Naked) gene (Grüneberg, loc. cit). All mice were bred and maintained at the Animal Genetics Section, C.S.I.R.O., University of Sydney.

The mice were skinned immediately after killing, the skins pinned on a cork frame, fixed in 70 per cent. alcohol, dehydrated, and cleared in xylol in order to remove fat; the skins were then passed through alcohol to water, stained for a few minutes in 0·25 per cent. methylene blue, dehydrated, cleared again, and mounted

* Animal Genetics Section, C.S.I.R.O., University of Sydney.

in "Siro". This treatment stains the hair follicles and muscles light blue, the connective tissue remaining practically unstained; the mast cells and their scattered granules are stained deep purple (Zahl and Nowak 1949). It is unfortunate that the growing follicles stain and obscure the view. The area of skin examined was a dorsal strip between neck and tail root, about 2 cm wide.

In course of the work, a new and simple method of preparing and staining mast cells was developed. Whole skins were fixed in 5 per cent. formol-saline to which about 1 per cent. iron oxide had been added. After 4–5 days in fixative, the skins were dehydrated, cleared in xylol, and mounted in "Siro". The mast cell granules stain selectively a bright straw-yellow colour, the rest of the tissue stains a uniform pale yellow.

Selected areas from the cleared skins were embedded in paraffin, cut serially at 20 μ, and mounted on slides in the usual way. Some paraffin sections were stained in 0·5 per cent. thionin dissolved in 20 per cent. alcohol; some were examined unstained for purposes explained in the next section.

The reason for using Naked mice is that in the skin of these mice it is sometimes possible to examine two complete hair growth cycles on one slide, with hair follicles in every desired stage of growth from anagen to telogen. The stages of the development of hair follicles in the mouse have been described in detail by Dry (1926).

III. Results

The main observations were as follows:

(i) In the areas of the skin where hair growth is in the resting phase, a high density of mast cells can be seen, many of them disintegrating and scattering their granules into the surrounding connective tissue.

(ii) The number of mast cells appears to be less in areas in active hair growth, an impression which may be misleading, because some of the mast cells in the dermis may be concealed by bulky hair follicles. Apart from this doubtful quantitative difference, there is clearly a difference in the shape of the mast cells in regions actively in the growth phase compared to regions in the resting phase. Mast cells in growing regions are compact and sharply outlined, and only occasionally can a disintegrating cell be found.

(iii) In areas of skin in which the follicles are in the early anagen stage, mast cells or their isolated granules can occasionally be found which do not stain purple but appear to be black, brown, or light brown, depending on the colour of the animal. In some preparations from black animals, whole nests of mast cells were observed which had turned black in colour. The phenomenon is not due to treatment, because the black mast cells can be seen under a dissecting microscope within a few minutes of killing the animal, and identified as bluish spots immediately after skinning. Most of the pigmented granules appear below, around, or clinging to the outer side of the dermal papilla, and in the loose connective tissue between the growing follicle and the loose subdermal connective tissue (see Plate 1, Fig. 1; Plate 2, Figs. 2, 3, and 4; Plate 3, Figs. 1, 2, and 3). Cells entirely filled with pigmented granules are always centered below the hair follicles. In iron oxide preparations, some cells can be seen in which the granules are of both kinds, some being straw-yellow and some pigmented.

This suggests that the cells with pigmented and non-pigmented granules are the same, the granules being converted into pigment in the pigmented cells.

In early anagen, the dermal papilla of the follicle is devoid of pigmented granules (Plate 2, Fig. 1). As the follicle grows, a few loose granules cling to the outside of the dermal papilla (Plate 2, Figs. 2 and 3), and at a later stage pass inside it and appear as a compact lump (Plate 2, Fig. 4). As the growth progresses, the lump of granules inside the dermal papilla becomes bigger and denser (Plate 3, Figs. 1 and 2) and the epidermal papilla starts to grow over it in an enveloping fashion (Plate 3, Figs. 3 and 4; Plate 4, Figs. 1 and 2). Finally, the whole lump is contained within the follicle filling the dermal papilla (Plate 4, Fig. 3). In some cases many granules remain outside the follicle, in the surrounding connective tissue, or clinging to the outside of the follicle (Plate 4, Fig. 3). At this stage the pigmented granules come into contact with the dendritic cells (Plate 4, Fig. 3) and the formation of hair pigment starts distal to the dendritic cells.

In the final stage, when the pigment in the hair is formed, the dermal papilla appears empty, except for a few remaining granules (Plate 4, Fig. 4) which disappear also after the hair is fully developed.

(iv) A great number of mast cells surround the arteries. There are no more mast cells around the veins than anywhere else in the surrounding tissue (see Plate 4, Fig. 3).

IV. Discussion

These observations, made on Naked and Crinkled mice, suggested that the pigmented mast cell granules outside and the granules inside the follicle were identical since all the intermediate stages of the "swallowing" of the granules by the papilla can be actually observed, as shown in Plates 2–4 and diagrammatically in Figure 1. Since in the full grown follicle all granules but a very few disappear from the dermal papilla (Plate 4, Fig. 4) and all the pigmented substance appears distal to the dendritic cells, we might suppose that these granules are used up in the development of the growing follicle.

If this is so, then in mice with reduced hair growth, such as Crinkled which has only 40 per cent. of the amount of hair in normal mice, a large number of granules should remain unused, provided the production of mast cells remains unimpaired.

All Crinkled mice of 6 months of age or above showed large numbers of pigmented granules and whole mast cells, turned black or brown depending on the coat colour of the animal, in the subdermal loose connective tissue sometimes stuck together in great lumps (Plate 1, Fig. 2). (Such residual granules can be observed in normal mice also, but only occasionally.)

It appears that mast cells, beside their function of producing heparin and histamine are also concerned in pigment formation and the growth of the hair follicle. The fact that the mast cell granules, either scattered or still inside the cell, turn to pigment in some cases suggests that the granules themselves are the precursors of the pigment in the follicle and that the mast cells contain a substance which can be converted into pigment. There is no pigment formation in the hair before the granules

enter the papilla (Plates 2–4). Dendritic cells (Plate 4, Fig. 3) come in immediate contact with the granules packed inside the dermal papilla. Pigment formation distal to the dendritic cells does not start until after contact between mast cell granules and dendritic cells has been established and, as the pigment formation in the hair progresses, the dermal papilla becomes depleted of granules. A depleted papilla is shown in Plate 4, Fig. 4, containing only a few isolated granules.

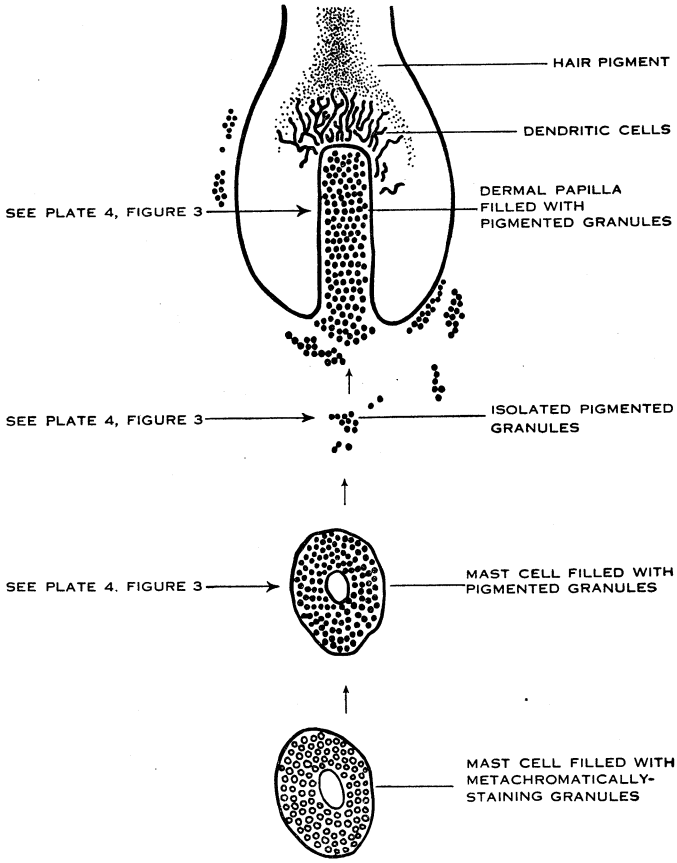

Fig. 1.—Schematic illustration of the mast cell pigment relationship.

Medawar (1944, 1945, 1946*a*, 1946*b*, 1948*a*, 1948*b*) and Billingham and Medawar (1950) have shown that pigment formation is closely connected with the pigmentary dendritic cells, and that pigment spread seems to be caused "by a serially propagable transformation of non-pigmentary into pigmentary dendritic cells by a cytoplasmic ingredient of the latter which is capable of behaving 'infectively'."

The observations described in the present paper show that the granules in mast cells may be converted to pigment without coming into immediate contact with the dendritic cells.

Two important facts must be emphasized about this transformation: (i) the transformation occurs primarily below and round the hair follicles, and (ii) the colour

of the transformed cells is always of the colour of the animal in question; black in black mice, brown in brown mice, light brown in diluted mice, very pale and just visible in chinchilla, an allele on the albino gene.

It must also be kept in mind that the transformation of mast cells into pigment outside the hair follicle is an abnormal process and may only indicate that under normal conditions the mast cells provide a "materia prima" which, after entering the hair follicle, is turned by dendritic cells into pigment, possibly after the dendritic cells have engulfed granules liberated by the mast cells, though this engulfing has not been observed. The intense metachromatic staining of the growing hair follicle which resembles the staining of mast cell granules seems to support such a view.

Two other possibilities may be considered: (iii) the mast cells and the dendritic cells independently follow different paths of pigment formation, and (iv) the mast cells receive pigment or pigmentary precursor from the follicular dendritic cells. At this stage, the author is unable to say without adequate experimental work what is the relationship of the dendritic cells to the pigmentary transformation of the mast cells; however, it seems to be sound, in face of the evidence, to discard these last two possibilities as unlikely.

V. Acknowledgments

I wish to thank Dr. J. M. Rendel and Professor P. D. F. Murray for advice and criticism. I am also indebted to Mr. K. Adams for preparing the photographic plates.

VI. References

Billingham, R. E., and Medawar, P. B. (1950).—*Heredity* **4**: 2.
Dry, F. W. (1926).—*J. Genet.* **16**: 287.
Ehrlich, P. (1877).—*Arch. mikr. Anat.* **13**: 63.
Grüneberg, H. (1952).—"Genetics of the Mouse." 2nd Ed. (Nijhoff: The Hague.)
Hirt, A. (1938).—*Verh. anat. Ges. Jena* **87**: 97-105.
Holmgren, H., and Wilander, O. (1937).—*Z. mikr.-anat. Forsch.* **42**: 242.
Jorpes, J. E., Holmgren, H., and Wilander, O. (1937).—*Z. mikr.-anat. Forsch.* **42**: 279–301.
Medawar, P. B. (1944).—*J. Anat., Lond.* **78**: 176.
Medawar, P. B. (1945).—*J. Anat., Lond.* **79**: 157.
Medawar, P. B. (1946*a*).—*Brit. J. Exp. Path.* **27**: 9.
Medawar, P. B. (1946*b*).—*Brit. J. Exp. Path.* **27**: 15.
Medawar, P. B. (1948*a*).—*Brit. J. Exp. Path.* **29**: 58.
Medawar, P. B. (1948*b*).—*Quart. J. Micr. Sci.* **89**: 239.
Riley, J. F. (1953*a*).—*J. Path. Bact.* **65**: 461, 471.
Riley, J. F. (1953*b*).—*Science* **118**: 332.
Riley, J. F. and West, G. B. (1953).—*J. Physiol.* **120**: 528.
Zahl, P. A., and Nowak, A. Jr. (1949).—*Stain Tech.* **24**: 185.

Explanation of Plates 1–4

Plate 1

Fig. 1.—Loose connective tissue between the dermal papilla packed with pigmented granules, and the subdermal loose connective tissue. Isolated mast cell granules scattered in the loose connective tissue. Unstained section (cf. Plate 2, Figs. 2, 3, and 4; Plate 3, Figs. 1, 2, and 3).

Fig. 2.—Lump of whole mast cells and their isolated granules, concentrated round a hair follicle, turned to pigment in the subdermal connective tissue of a Crinkled mouse. Unstained.

Fig. 3.—Mouse skin, whole mount, stained in methylene blue. *A*, artery; *V*, vein.

MAST CELLS AND HAIR GROWTH IN THE MOUSE

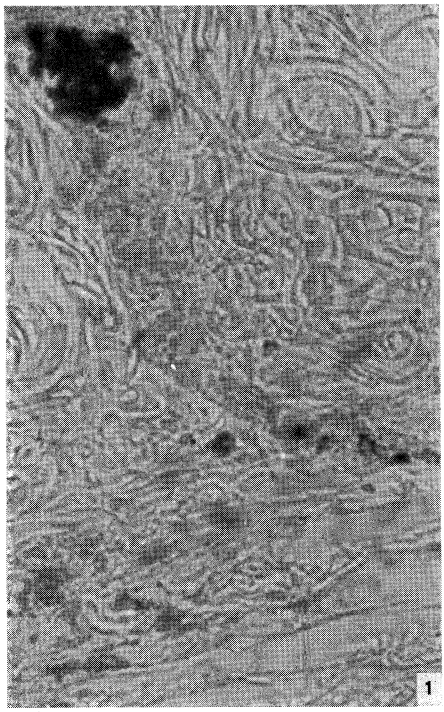

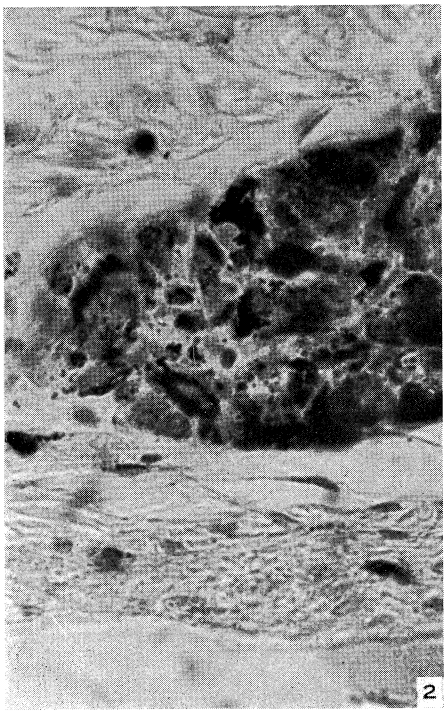

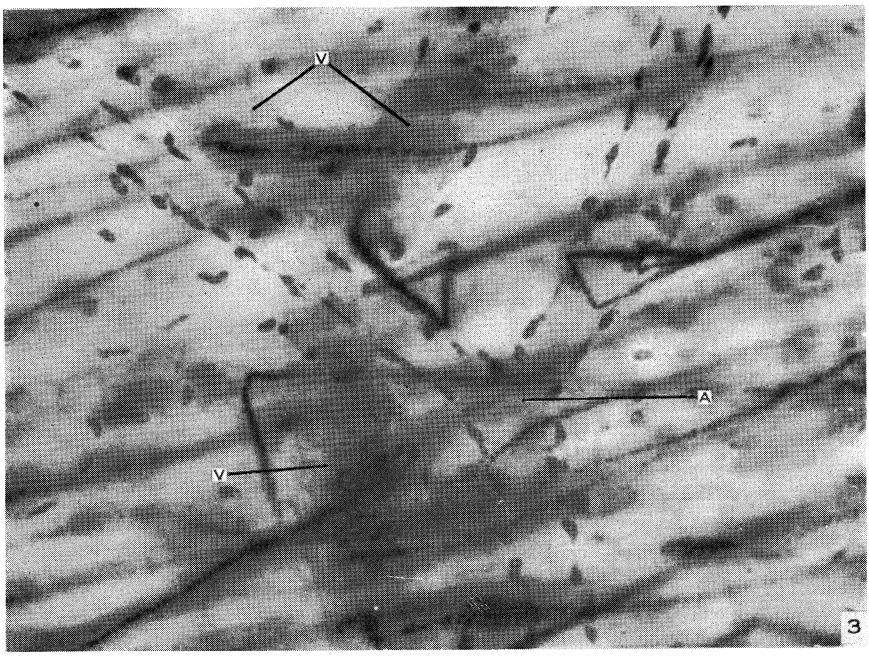

MAST CELLS AND HAIR GROWTH IN THE MOUSE

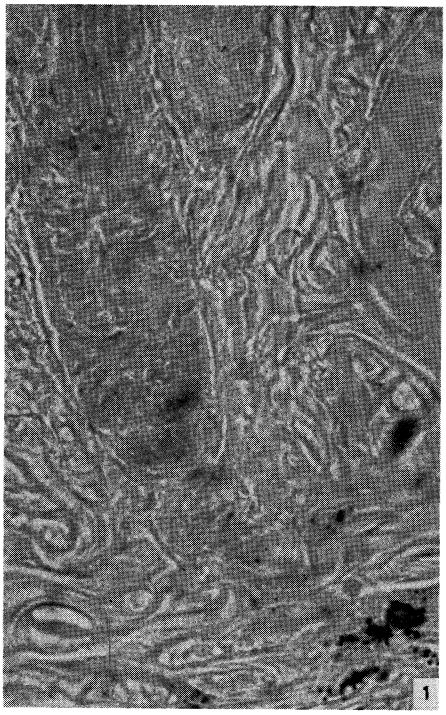

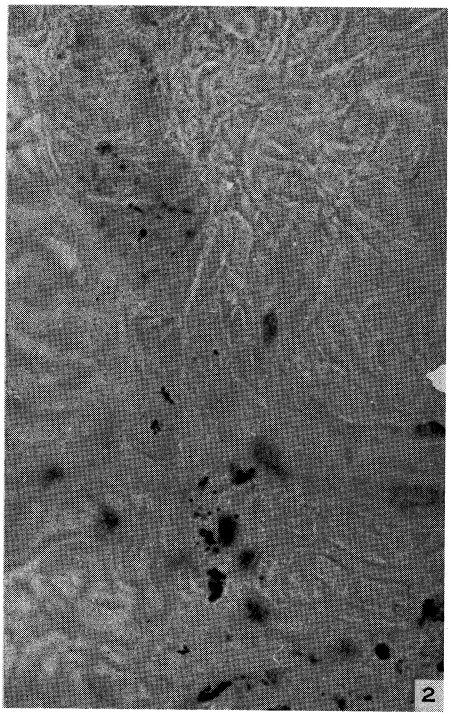

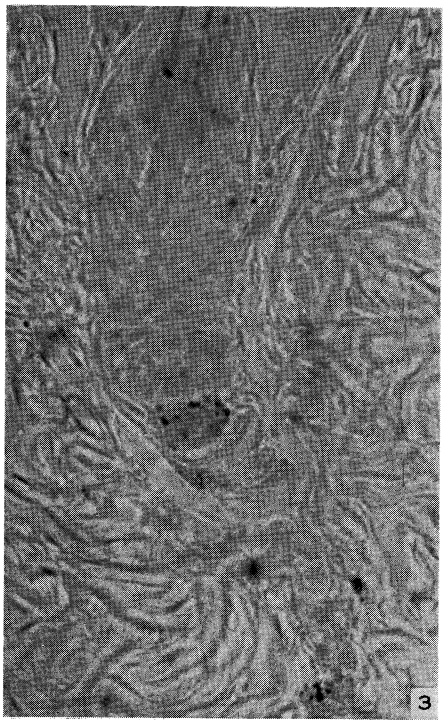

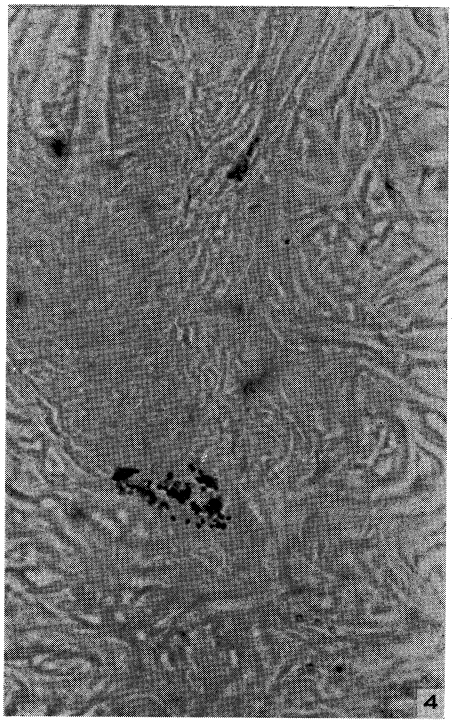

MAST CELLS AND HAIR GROWTH IN THE MOUSE

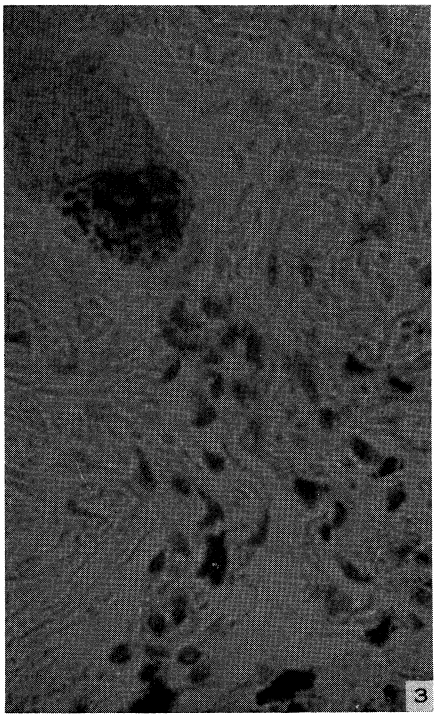

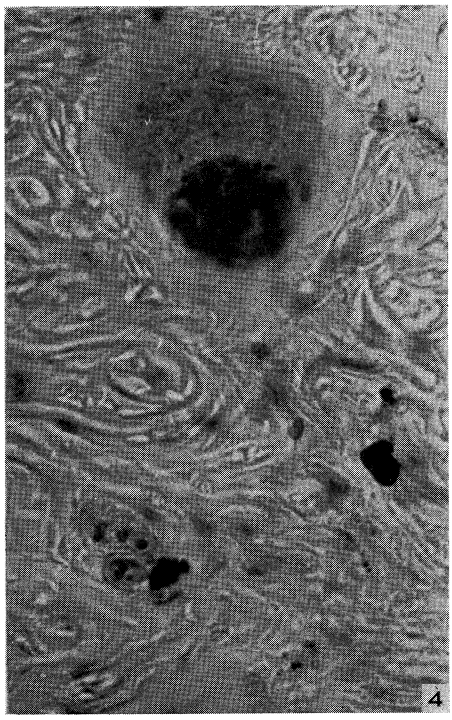

MAST CELLS AND HAIR GROWTH IN THE MOUSE

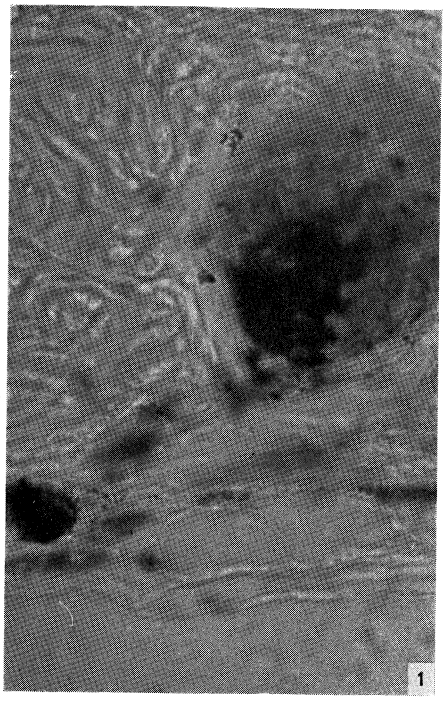

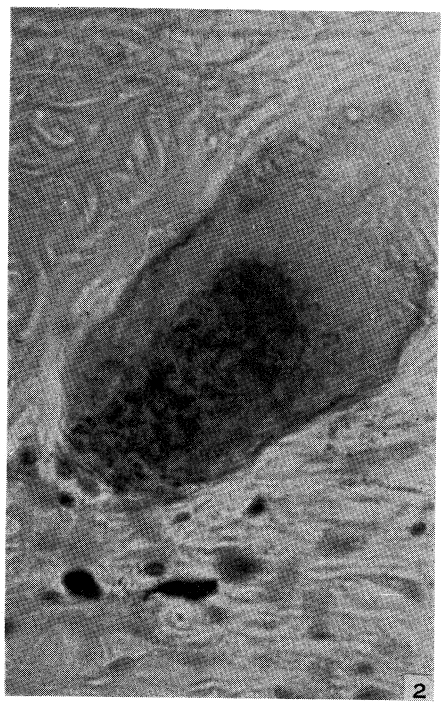

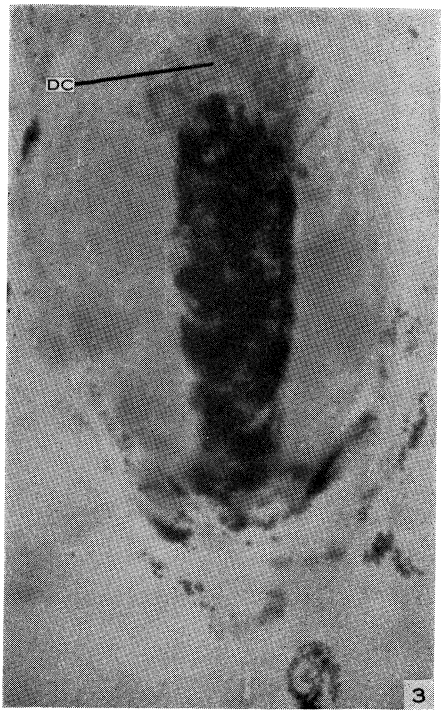

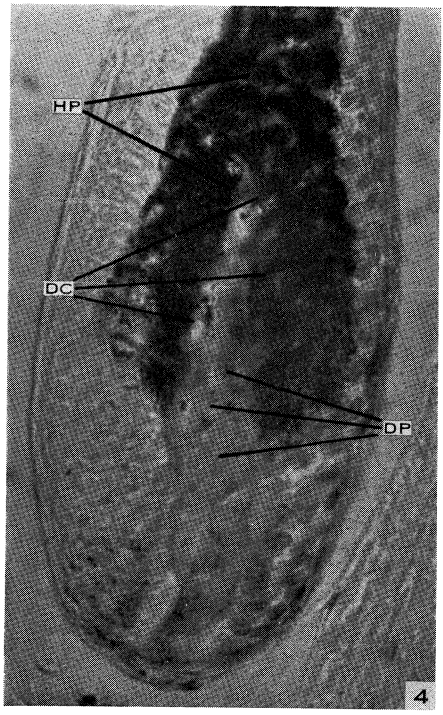

PLATE 2

Fig. 1.—Dermal papilla in very early anagen, free from any pigment. Pigmented mast cells can be seen in the left lower corner of the figure. Unstained.

Fig. 2.—Isolated pigmented granules clinging to the outside of the dermal papilla of a growing hair follicle in early anagen. Note granule in the path of the growing follicle. Unstained.

Fig. 3.—Few pigmented granules can be seen inside the dermal papilla. Unstained.

Fig. 4.—Pigmented granules begin to concentrate in and round the dermal papilla. Unstained.

PLATE 3

Fig. 1.—Lump of pigmented granules becoming more compact. Note scattered mast cell granules in the loose connective tissue funnel below the follicle. Unstained.

Fig. 2.—Epidermal papilla begins to grow in an enveloping fashion round the lump of granules concentrated in and around the dermal papilla. Stained faintly in alcoholic thionin.

Fig. 3.—The same as for Plate 3, Figure 2, but in slightly more advanced stage. Note the loose connective tissue funnel below the follicle. Stained in alcoholic thionin.

Fig. 4.—The same as for Plate 3, Figure 3, but in more advanced stage. Stained in alcoholic thionin.

PLATE 4

Fig. 1.—Hair follicle in advanced growth stage, approaching subdermal loose connective tissue. The pigmented granule lump is almost swallowed by epidermal papilla. Pigmented mast cells are in front of the follicle, and some isolated granules scattered around the follicle. Stained in alcoholic thionin.

Fig. 2.—Similar stage to Plate 4, Figure 1, in side view. Stained in alcoholic thionin.

Fig. 3.—Dermal papilla filled completely with black pigmented granules. Scattered black granules are round the follicle in the surrounding connective tissue, one complete mast cell is filled with black granules in front of the follicle. Dendritic cells *(DC)* become visible on the distal end of the dermal papilla. Note lack of pigment distal from dendritic cells. Whole mount stained faintly with methylene blue.

Fig. 4.—Hair follicle in telogen stage. The pigmented granules, except for a very few, have disappeared from the dermal papilla. Hair pigment *(HP)* has appeared distal from the region occupied by the dendritic cells *(DC)*. *DP*, dermal papilla with isolated mast cell granules.