The Royal New Zealand College of General Practitioners
Te Whare Tohu Rata o Aotearoa

Ocular syphilis: connecting the dots

Jiyeon Kim MBChB, PGDipOMG, PGDipOphthBS;[1,3] Jonathan G. Ussher MBChB, DCH[2]

[1] Eye Department, Canterbury DHB, Christchurch, New Zealand
[2] Eye Clinic, Christchurch Hospital, Christchurch, New Zealand
[3] Corresponding author. Email: cool_meant@hotmail.com

J PRIM HEALTH CARE
2019;11(1):12–13
doi:10.1071/HC18065
Received 26 August 2018
Accepted 10 December 2018
Published 23 January 2019

Introduction

Syphilis is a bacterial infection caused by *Treponema pallidum*, typically spread through sexual contact.[1] Syphilis can manifest with various systemic signs and symptoms, and presents differently depending on the stage of the disease, often being referred to as the great imitator. Obtaining a careful history, with attention to sexual history and a review of systems, is crucial in reaching the correct diagnosis. Early diagnosis and treatment are important to reduce the likelihood of future complications and transmission rates.

Case report

A male aged in his 60s was referred to the ophthalmology clinic by his optometrist for review of a dense floater in his left eye. He had been experiencing bilateral floaters for a month. The left eye continued to deteriorate, with significant reduction in visual acuity. No other eye symptoms such as pain, flashes of light or visual field defects were reported. On further questioning, the patient had been troubled with multiple systemic symptoms such as fever, chills, widespread rash (Figure 1), mouth ulcers, sore throat and a painless genital lesion for ~4 months. However, he had only raised individual symptoms on separate visits to his general practitioner (GP). Understandably, he was given multiple common diagnoses such as: pharyngitis, Grover's disease and flu-like illness, which adequately explained the presenting complaint on each occasion. It was not until late in the course at the ophthalmology clinic after concern for a sexually transmitted infection (STI) had been expressed to him and his sexual history re-taken, that he reluctantly admitted to having had a recent male sexual contact. The last sexual encounter had taken place shortly before the onset of symptoms. He had not disclosed this information to his GP as he lived in a small community and feared being stigmatised.

Figure 1. Rash secondary to secondary syphilis

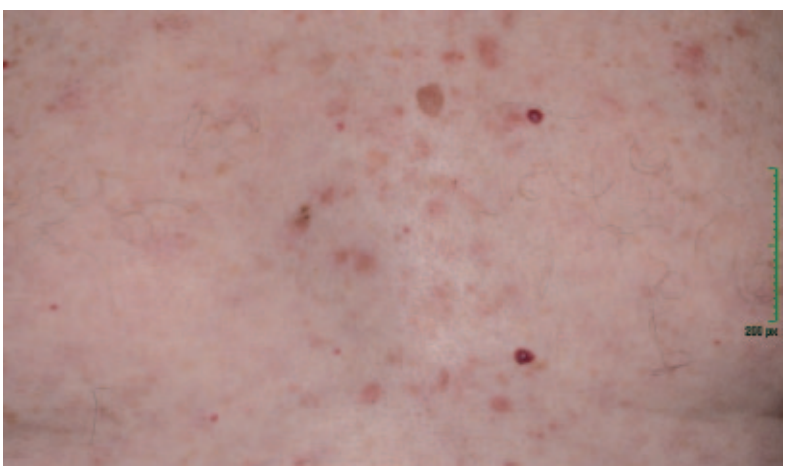

On examination, the patient's visual acuity was only 'count fingers' in the left eye. He had bilateral anterior uveitic inflammation as well as severe vitritis with snowball formation (inflammatory cells) in the left posterior segment. No obvious sign of choroiditis, retinitis or optic neuropathy was seen.

These findings were consistent with neurosyphilis. We proceeded with serology testing to check for various infections and autoimmune-driven conditions. The *Treponema pallidum* haemagglutination (TPHA) and Recombinase Polymerase Amplification (RPA) tests later came back reactive. Human immunodeficiency virus (HIV) serology was negative. He was referred to the Sexual Health Disease team and admitted for intensive intravenous benzyl-penicillin treatment over 14 days. His symptoms improved remarkably by the end of his admission. His visual acuity improved to 6/6 in each eye.

CSIRO Publishing
Journal Compilation © Royal New Zealand College of General Practitioners 2019
This is an open access article licensed under a Creative Commons Attribution-NonCommercial-NoDerivatives 4.0 International License

Discussion

Syphilis can be divided into three different phases: primary, secondary and tertiary infection. Primary infection occurs ~3–90 days post exposure.[1] Patients usually present with a painless skin lesion at the point of contact, known as chancre. Secondary infection occurs ~4–10 weeks post exposure.[1] It often involves skin, mucous membranes and lymph nodes. Patients commonly complain of sore throat, mouth ulcer, headache, weight loss, symmetrical erythematous non-pruritic skin rash especially on the palms and soles. If left untreated, patients can develop tertiary syphilis, also known as neurosyphilis, with central nervous system involvement. This is potentially life-threatening and if suspected, it is essential for treatment to be commenced immediately for optimum outcomes.[2] Although rare, ocular involvement can occur during this phase with optic neuritis, uveitis and interstitial keratitis; this is called ocular syphilis.[3] It is generally accepted that patients with ocular involvement get treated in the same way as patients with neurosyphilis.[2]

Incidence rates for syphilis have increased both in New Zealand and internationally.[4–6] Syphilis incidence per annum in New Zealand has increased from 143 in 2014 to 472 in 2017. In Mid-central District Health Board, syphilis cases increased from 1 to 15 per annum during the same period of time.[7] As syphilis is an STI, it carries a social stigma. Studies show that patients feel hesitant to come forward with their symptoms when an STI is suspected.[8,9] Some patients may try to hide the potential linkage between their symptoms and sexual history, despite thinking the two could be related. This was a challenge in this case, as the patient had actively filtered and restricted the information he offered to his GP in order to avoid possible judgement. This created significant confusion and contributed to misdiagnosis. Once he was reassured that he was in a safe environment and the importance of an accurate history was explained to him, the patient disclosed the full information. Although, at that point, the high clinical suspicion for syphilis meant proceeding with further investigations regardless of the history; successful acquisition of this history would have likely meant earlier diagnosis and reduction in the sequelae of the disease.

This case emphasises how vital full disclosure from the patient is when developing a synergistic doctor–patient relationship, and is an important reminder that as doctors, we must keep an open mind about patients' risk profiles and avoid any assumptions. It also highlights the need to consider a broader view of patients' health and to resist the pressure, driven by a time-poor working environment, to zero in on simple explanations, otherwise, we risk not connecting the dots.

Competing interests

The authors declare no competing interest.

Acknowledgement

We declare that we have not received any specific funding for this article.

References

1. Ngan V, Vanousova D. Syphilis. Czech Republic. DermNet; 2015. [cited 2018 July 23]. Available from: https://www.dermnetnz.org/topics/syphilis/
2. Sood AB. Syphilitic uveitis. American Academy of Ophthalmology. Oklahoma City: EyeWiki; 2018. [cited 2018 July 23]. Available from: http://eyewiki.aao.org/Syphilitic_Uveitis
3. Wade M. Be on the lookout for ocular syphilis. Clinical Update. Oklahoma City: AAO, 2015. [cited 2018 July 23]. Available from: https://www.aao.org/eyenet/article/be-on-lookout-ocular-syphilis
4. Ministry of Health. Syphilis. Wellington: Ministry of Health; 2018. [cited 2018 July 23]. Available from: https://www.health.govt.nz/your-health/conditions-and-treatments/diseases-and-illnesses/syphilis
5. Azariah S. Auckland: city of syphilis? N Z Med J. 2016;129(1447):57–63.
6. Cunningham B. Rise in syphilis cases prompts calls to practise safe sex. Wellington: Ministry of Health; 2018. [cited 2018 July 23]. Available from: https://www.health.govt.nz/news-media/media-releases/rise-syphilis-cases-prompts-calls-practise-safe-sex
7. Ministry of Health. Public Health Surveillance. Wellington: Ministry of Health; 2018. [cited 2018 July 23]. Available from: https://surv.esr.cri.nz/index.php
8. Rusch M, Shoveller J, Burgess S, et al. Association of sexually transmitted disease-related stigma with sexual health care among women attending a community clinic program. Sex Transm Dis. 2008;35(6):553–7. doi:10.1097/OLQ.0b013e3181685855
9. Cunningham SD, Tschann J, Gurvey JE, et al. Attitudes about sexual disclosure and perceptions of stigma and shame. Sex Transm Infect. 2002;78:334–8. doi:10.1136/sti.78.5.334